


Canon



**Clinical
evidence**

Aplio

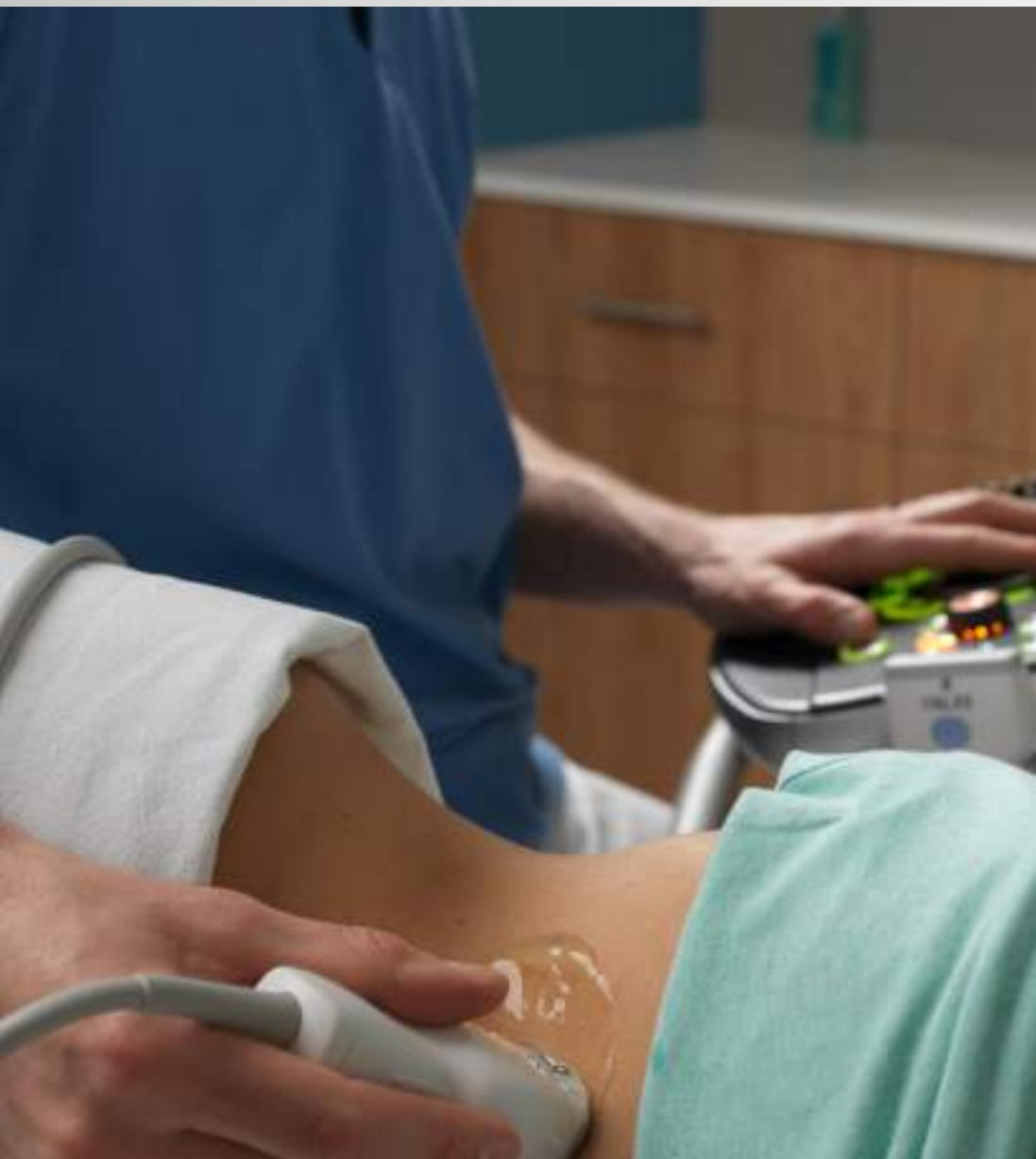

Glossary

- ATI* – Attenuation Imaging
- CEUS* – Contrast-Enhanced Ultrasound
- MPI* – Myocardial Performance Index
- MVA* – Mitral Valve Analysis
- NLV* – Normalized Local Variance
- SMI* – Superb Micro-vascular Imaging
- SWD* – Shear Wave Dispersion
- SWE* – Shear Wave Elastography
- WMT* – Wall Motion Tracking



Content	
General imaging	2
Pediatric imaging	24
Musculoskeletal ultrasound	28
Women's Health imaging	34
Obstetric ultrasound	40
Echocardiography	44
Vascular imaging	48



General imaging



Post-COVID-19 Liver Injury: Comprehensive Imaging With Multiparametric Ultrasound

Radzina M, Putrins DS, Micena A, Vanaga I, Kolesova O, Platkajis A, Viksna L

J Ultra Med 2021; online ahead of print

<https://doi.org/10.1002/jum.15778>



Reduction of Shear Wave Elastography but Not Shear Wave Dispersion After Successful Hepatitis C Treatment With Direct-Acting Antiviral Agents

Su PY, Su WW, Wu LS, Hsu PK, Huang SP, Hsu YC

J Ultras Med 2021;40(9):1919-1926

<https://doi.org/10.1002/jum.15576>



Shear Wave Elastography and Shear Wave Dispersion Imaging in the Assessment of Liver Disease in Alpha1-Antitrypsin Deficiency

Schulz M, Kleinjans M, Strnad P, Demir M, Holtmann TM, Tacke F, Wree A

Diagnostics 2021;11(4):629

<https://doi.org/10.3390/diagnostics11040629>



Assessment of chronic liver disease by multiparametric ultrasound: results from a private practice outpatient facility

Aitharaju V, De Silvestri A, G. Barr R

Abdom Radiol 2021; online ahead of print

<https://doi.org/10.1007/s00261-021-03225-2>



The Role of Multiparametric US of the Liver for the Evaluation of Nonalcoholic Steatohepatitis

Sugimoto K, Moriyasu F, Oshiro H, Takeuchi H, Abe M, Yoshimasu Y, Kasai Y, Sakamaki K, Hara T, Itoi T

***Radiology* 2020;296(3):532-540**

<https://doi.org/10.1148/radiol.2020192665>



Reliability of Performing Multiparametric Ultrasound in Adult Livers

Gao J, Lee R, Trujillo M

***J Ultras Med* 2021; online ahead of print**

<https://doi.org/10.1002/jum.15751>



Accuracy of 2-dimensional Shear Wave Elastography and Attenuation Imaging for Evaluation of Patients with Nonalcoholic Steatohepatitis

Lee DH, Cho EJ, Bae JS, Lee JY, Yu SJ, Kim H, Lee KB, Han JK, Choi BI

***Clin Hepatol Gastroenterol* 2021;19(4):797-805**

<https://doi.org/10.1016/j.cgh.2020.05.034>



Diagnostic Performance of 2-D Shear-Wave Elastography with Propagation Maps and Attenuation Imaging in Patients with Non-Alcoholic Fatty Liver Disease

Podrug K, Sporea I, Lupusoru R, Pastrovic F, Mustapic S, Bâldea V, Bozin T, Bokun T, Salkic N, Şirli R, Popescu A, Puljiz Z, Grgurevic I

***Ultras Med Biol* 2021;47(8):2128-2137**

<https://doi.org/10.1016/j.ultrasmedbio.2021.03.025>



Efficacy of shear wave elastography for assessment of liver function in patients with heart failure

Nakayama R, Takaya Y, Nakamura K, Toh N, Ito H

***ESC Heart Failure* 2021;8(3):1751-1758**

<https://doi.org/10.1002/ehf2.13318>



Liver shear wave elastography and attenuation imaging coefficient measures: prospective evaluation in healthy children

Cailloce R, Tavernier E, Brunereau L, Fievet A, Falip C, Dujardin F, Willot S, Patat F, Morel B

***Abdom Radiol* 2021;46:4629–4636**

<https://doi.org/10.1007/s00261-021-02960-w>



The effect of water intake on ultrasound tissue characteristics and hemodynamics of adult livers

Lee J, Lee R, Erpelding T, Siddoway R L, Gao J

***Clin Exp Hepatol* 2021;7(2):223-230**

<https://doi.org/10.5114/ceh.2021.107068>



Quantification of Steatosis and Fibrosis using a new system implemented in an ultrasound machine

Sporea I, Bâldea V, Lupuşoru R, Bende F, Mare R, Lazăr A, Popescu A, Şirli R

***Med Ultrason* 2020;22(3):265-271**

<http://dx.doi.org/10.11152/mu-2495>



Comparison of liver stiffness assessment by transient elastography and shear wave elastography using six ultrasound devices

Iijima H, Tada T, Kumada T, Kobayashi N, Yoshida M, Aoki T, Nishimura T, Nakano C, Ishii A, Takashima T, Sakai Y, Aizawa N, Nishikawa H, Ikeda N, Iwata Y, Enomoto H, Ide Y, Hirota S, Fujimoto J, Nishiguchi S

***Hepatology* 2019;49(6):676–686**

<https://doi.org/10.1111/hepr.13319>



Ultrasound Shear Wave Elastography and Doppler Sonography to Assess the Effect of Hydration on Human Kidneys: A Preliminary Observation

Gao J, Thai A, Lee J, Fowlkes JB

***Ultrasound in Medicine and Biology* 2020;46(5):1179-1188**

<https://doi.org/10.1016/j.ultrasmedbio.2020.01.011>



An initial trial of quantitative evaluation of autoimmune pancreatitis using shear wave elastography and shear wave dispersion in transabdominal ultrasound

Suzuki H, Ishikawa T, Ohno E, Iida T, Uetsuki K, Yashika J, Yamada K, Yoshikawa M, Furukawa K, Nakamura M, Honda T, Ishigami M, Kawashima H, Fujishiro M

***Pancreatology* 2021;21(4):682-687**

<https://doi.org/10.1016/j.pan.2021.02.014>



Can Viscoelasticity Measurements Obtained Through Shear-Wave US Elastography be used to Monitor Hepatic Ischemia-Reperfusion Injury and Treatment Response? An Animal Study

Tang Y, Kong W, Zhao J, Chen Y, Liu L, Zhang G

***Ultrasound in Medicine and Biology* 2020;46(9):2464-2471**

<https://doi.org/10.1016/j.ultrasmedbio.2020.04.021>



What is the role of measuring shear wave dispersion using shear wave elastography in pancreatic parenchyma?

Suzuki H, Kawashima H, Ohno E, Ishikawa T, Hashimoto S, Nakamura M, Miyahara R, Ishigami M, Hirooka Y, Fujishiro M
***J Med Ultrasonics* 2020;47:575–581**

<https://doi.org/10.1007/s10396-020-01033-7>



Performance and cutoffs for liver fibrosis staging of a two-dimensional shear wave elastography technique

Ferraioli G, Maiocchi L, Dellafiore C, Tinelli C, Above E, Filice C
***Eur J Gastroenterol Hepatol* 2021;33(1):89-95**

<https://doi.org/10.1097/meg.0000000000001702>



Liver Shear Wave Speed and Other Quantitative Ultrasound Measures of Liver Parenchyma: Prospective Evaluation in Healthy Children and Adults

Trout AT, Xanthakos SA, Bennett PS and Dillman JR
***Am J Roentgenol* 2020;214(3):557-565**

<https://doi.org/10.2214/ajr.19.21796>



The Role of Multiparametric US of the Liver for the Evaluation of Nonalcoholic Steatohepatitis

Sugimoto K, Moriyasu F, Oshiro H, Takeuchi H, Abe M, Yoshimasu Y, Kasai Y, Sakamaki K, Hara T, Itoi T
***Radiology* 2020;296(3):532-540**

<https://doi.org/10.1148/radiol.2020192665>



Shear-Wave Dispersion Slope from US Shear-Wave Elastography: Detection of Allograft Damage after Liver Transplantation

Lee DH, Lee JY, Bae JS, Yi NJ, Lee KW, Suh KS, Kim H, Lee KB, Han JK

***Radiology* 2019;293(2):327-333**

<https://doi.org/10.1148/radiol.2019190064>



Usefulness of Transabdominal Shear Wave Elastography in Pancreatic Lesion

Kojima H, Sofuni A, Sugimoto K, Tsuchiya T, Ishii K, Tanaka R, Tanozuka R, Honjo M, Mukai S, Mitsuru F, Yamamoto K, Matsunami Y, Asai Y, Nagai K, Kurosawa T, Itoi T

***Gastroenterology* 2019;156(6S1):S-1045**

[http://dx.doi.org/10.1016/S0016-5085\(19\)39567-8](http://dx.doi.org/10.1016/S0016-5085(19)39567-8)



Preliminary clinical experience with shear wave dispersion (SWD) imaging of the liver

Zelesco M, Welman CJ, & Abbott S

***Ultras Med Biol* 2019;45(S):S25**

<https://doi.org/10.1016/j.ultrasmedbio.2019.07.493>



Comparison of liver stiffness measurements by a 2D-shear wave technique and transient elastography: results from a European prospective multi-centre study

Ronot M, Ferraioli G, Müller HP, Friedrich-Rust M, Filice C, Vilgrain V, Cosgrove D, Lim AK

***Eur Radiol* 2021;31:1578–1587**

<https://doi.org/10.1007/s00330-020-07212-x>



Repeatability and Agreement of Shear Wave Speed Measurements in Phantoms and Human Livers Across 6 Ultrasound 2-Dimensional Shear Wave Elastography Systems

Gilligan LA, Trout AT, Bennett P, Dillman J

***Investigative Radiol* 2020;55(4):191-199**

<https://doi.org/10.1097/rli.0000000000000627>



Non-invasive imaging biomarkers to assess nonalcoholic fatty liver disease: A review

Trujillo MJ, Chen J, Rubin JM, Gao J

***Clin Imaging* 2021;78:22-34**

<https://doi.org/10.1016/j.clinimag.2021.02.039>



Intra-System Reliability Assessment of 2-Dimensional Shear Wave Elastography

Edwards C, Cavanagh E, Kumar S, Clifton V, Fontanarosa D

***Appl Sci* 2021;11(7):2992**

<https://doi.org/10.3390/app11072992>



2D shear wave elastography is better than transient elastography in predicting post-hepatectomy complication after resection

Lee DH, Lee ES, Bae JS, Lee JY, Han JK, Yi NJ, Lee KW, Suh KS, Kim H, Lee KB, Choi BI

***Eur Radiol* 2021;31:5802-5811**

<https://doi.org/10.1007/s00330-020-07662-3>



***Test-retest repeatability of ultrasonographic shear wave elastography in a rat liver fibrosis model: toward a quantitative biomarker for preclinical trials**

Shin Y, Huh J, Ham SJ, Cho YC, Choi Y, Woo DC, Lee J, Kim KW

***Ultrasonography* 2021;40(1):126-135**

<https://doi.org/10.14366/usg.19088>



Two-Dimensional-Shear Wave Elastography with a Propagation Map: Prospective Evaluation of Liver Fibrosis Using Histopathology as the Reference Standard

Lee DH, Lee ES, Lee JY, Bae JS, Kim H, Lee KB, Yu SJ, Cho EJ, Lee JH, Cho YY, Han JK, Choi BI

***Korean J Radiol* 2020;21(12):1317-1325**

<https://doi.org/10.3348/kjr.2019.0978>



Comparison of the clinical usefulness of shear wave elastography relative to transient elastography and other markers of liver fibrosis.

Ayonrinde OT, Abbott S, Welman CJ, Adris N, Perrin M, Connelly C, Lam W, Zelesco M

***Ultras Med Biol* 2019;45(S1):S80**

<https://doi.org/10.1016/j.ultrasmedbio.2019.07.273>



Differentiating cervical metastatic lymphadenopathy and lymphoma by shear wave elastography

Chae SY, Jung HN, Ryoo I, Suh S

***Sci Rep* 2019;9:12396**

<https://doi.org/10.1038/s41598-019-48705-0>



Accuracy of the ultrasound attenuation coefficient for the evaluation of hepatic steatosis: a systematic review and meta-analysis of prospective studies

Jang JK, Choi SH, Lee JS, Kim SY, Lee SS, Kim KW

Ultrasonography 2021; online ahead print

<https://doi.org/10.14366/usg.21076>



Usefulness of US attenuation imaging for the detection and severity grading of hepatic steatosis in routine abdominal ultrasonography

Kwon EY, Kim YR, Kang DM, Yoon KH, Lee YH

Clin Imaging 2021;76:53-59

<https://doi.org/10.1016/j.clinimag.2021.01.034>



Accuracy of US AC for Evaluation of Hepatic Steatosis: A Systematic Review and Meta-analysis of Prospective Studies

Jang JK, Choi SH, Lee JS, Kim SY, Lee SS, Kim KW

Ultrasonography 2021; online ahead print

<https://doi.org/10.14366/usg.21076>



Performance of the Attenuation Imaging Technology in the Detection of Liver Steatosis

Ferraioli G, Maiocchi L, Savietto G, Tinelli C, Nichetti M, Rondanelli M, Calliada F, Preda L, Filice C

J Ultras Med 2021;40(7):1325-1332

<https://doi.org/10.1002/jum.15512>



Reproducibility of ultrasound attenuation imaging for the noninvasive evaluation of hepatic steatosis

Yoo J, Lee JM, Joo I, Lee DH, Yoon JH, Kang HJ, Ahn SJ
***Ultrasonography* 2020;39(2):121-129**

<https://dx.doi.org/10.14366%2Fusg.19034>



Attenuation Imaging with Ultrasound as a Novel Evaluation Method for Liver Steatosis

Hsu PK, Wu LS, Yen HH, Huang HP, Chen YY, Su PY, Su WW
***J Clin Med* 2021;10(5):965**

<http://dx.doi.org/10.3390/jcm10050965>



Ultrasound-Based Attenuation Imaging for the Non-Invasive Quantification of Liver Fat – A Pilot Study on Feasibility and Inter-Observer Variability

Jesper D, Klett D, Schellhaas B, Pfeifer L, Leppkes M, Waldner M, Neurath MF and Strobel D

***IEEE J Transl Eng Health Med* 2020;8:1-9**

<https://doi.org/10.1109/JTEHM.2020.3001488>



Quantification of hepatic steatosis with ultrasound: promising role of attenuation imaging coefficient in a biopsy-proven cohort

Dioguardi Burgio M, Ronot M, Reizine E, Rautou PM, Castera L, Paradis V, Garteiser P, Van Beers B, Vilgrain V

***Eur Radiol* 2020;30:2293–2301**

<https://doi.org/10.1007/s00330-019-06480-6>



Detection of Liver Steatosis with a Novel Ultrasound-Based Technique: A Pilot Study Using MRI-Derived Proton Density Fat Fraction as the Gold Standard

Ferraioli G, Maiocchi L, Raciti MV, Tinelli C, De Silvestri A, Nichetti M, De Cata P, Rondanelli M, Chiovato L, Calliada F, Filice C

***Clin Transl Gastroenterol* 2019;10(10)e00081**

<https://doi.org/10.14309/ctg.0000000000000081>



Ultrasound-based techniques for the diagnosis of liver steatosis

Ferraioli G, Soares Monteiro LB

***World J Gastroenterol* 2019;25(40):6053-6062**

<https://dx.doi.org/10.3748/wjg.v25.i40.6053>



Usefulness of Attenuation Imaging with an Ultrasound Scanner for the Evaluation of Hepatic Steatosis

Tada T, Iijima H, Kobayashi N, Yoshida M, Nishimura T, Kumada T, Kondo R, Yano H, Kage M, Nakano C, Aoki T, Aizawa N, Ikeda N, Takashima T, Yuri Y, Ishii N, Hasegawa K, Takata R, Yoh K, Sakai Y, Nishikawa H, Iwata Y, Enomoto H, Hirota S, Fujimoto J, Nishiguchi S

***Ultras Med Biol* 2019;45(10):2679-2687**

<https://doi.org/10.1016/j.ultrasmedbio.2019.05.033>



Assessment of hepatic steatosis by using attenuation imaging: a quantitative, easy-to-perform ultrasound technique

Bae JS, Lee DH, Lee JY, Kim H, Yu SJ, Lee JH, Cho EJ, Lee YB, Han JK, Choi BI

***Eur Radiol* 2019;29:6499-6507**

<https://doi.org/10.1007/s00330-019-06272-y>



Prospective Evaluation of Hepatic Steatosis Using
Ultrasound Attenuation Imaging in Patients with Chronic
Liver Disease with Magnetic Resonance Imaging Proton
Density Fat Fraction as the Reference Standard

Jeon SK, Lee JM, Joo I, Yoon JH, Lee DH, Lee JY, Han JK

***Ultras Med Biol* 2019;45(6):1407-1416**

<https://doi.org/10.1016/j.ultrasmedbio.2019.02.008>



Preliminary Clinical Experience with Shear Wave
Dispersion Imaging for Liver Viscosity in Preoperative
Diagnosis of Focal Liver Lesions

Dong Y, Qiu Y, Zhang Q, Yang D, Yu L, Wang WP, Dietrich CF

***Z Gastroenterol* 2020;58(09):847-854**

<https://doi.org/10.1055/a-1217-7465>



Shear Wave Dispersion Predicts Liver Fibrosis and
Adverse Outcomes in Patients with Heart Failure

Ohara H, Yoshihisa A, Ishibashi S, Matsuda M, Yamadera Y, Sugawara Y,
Ichijo Y, Hotsuki Y, Watanabe K, Anzai F, Sato Y, Kimishima Y,
Yokokawa T, Misaka T, Sato T, Oikawa M, Kobayashi A, Takeishi Y

***J Clin Med* 2020;9(12):3953**

<https://doi.org/10.3390/jcm9123953>



Clinical utilization of shear wave dispersion imaging in
diffuse liver disease

Sugimoto K, Moriyasu F, Oshiro H, Takeuchi H, Yoshimasu Y, Kasai Y,
Itoi T

***Ultrasonography* 2020;39(1):3-10**

<https://doi.org/10.14366/usg.19031>



Prospective Validation of Repeatability of Shear Wave Dispersion Imaging for Evaluation of Non-alcoholic Fatty Liver Disease

Yoo J, Lee JM, Joo I, Lee DH, Yoon JH, Kang HJ, Ahn SJ

***Ultras Med Biol* 2019;45(10):2688-2696**

<https://doi.org/10.1016/j.ultrasmedbio.2019.06.411>



Quantitative Assessment of Fatty Liver using Ultrasound with Normalized Local Variance Technique

Bae JS, Lee DH, Lee JY, Kim H, Yu SJ, Lee JH, Cho EJ, Lee YB, Han JK, Choi BI

***Ultraschall Med* 2020; online ahead of print**

<https://doi.org/10.1055/a-1143-3091>



Quantitative Evaluation of Hepatic Steatosis Using Normalized Local Variance in a Rat Model: Comparison with Histopathology as the Reference Standard

Bae JS, Lee JY, Lee DH, Kim H, Lee Y, Han JK

***Korean J Radiol* 2019;20(9):1399-1407**

<https://doi.org/10.3348/kjr.2019.0068>



Comparison of Super-Resolution US and Contrast Material-enhanced US in Detection of the Spoke Wheel Sign in Patients with Focal Nodular Hyperplasia

Kang TW, Jeong WK, Kim YY, Min JH, Kim YK, Kim SH, Sinn DH, Kim K

***Radiology* 2021;298(1):82-90**

<https://doi.org/10.1148/radiol.2020200885>



Superb microvascular imaging technology of ultrasound examinations for the evaluation of tumor vascularity in hepatic hemangiomas

Jeon SK, Lee JY, Han JK

***Ultrasonography* 2021;40(4):538-545**

<https://doi.org/10.14366/usg.20177>



Quantitative Assessment of Salivary Gland Parenchymal Vascularization Using Power Doppler Ultrasound and Superb Microvascular Imaging: A Potential Tool in the Diagnosis of Sjögren's Syndrome

Ustabasioglu FE, Korkmaz S, Ilgen U, Solak S, Kula O, Turan S, Emmungil H

***Balkan Med J* 2020;37(4):203-207**

<https://doi.org/10.4274/balkanmedj.galenos.2020.2019.11.91>



Diagnostic Value of Superb Microvascular Imaging in Parotid Tumors

Zhao L, Mu J, Mao Y, Xin X

***Med Sci Monit* 2020;26:e921813**

<https://pubmed.ncbi.nlm.nih.gov/32507848/>



Distinguishing benign from malignant thyroid nodules by using thyroid ultrasonography: utility of adding superb microvascular imaging

Ahn HS, Ha SM, Park HJ, Lee GY, Kim S, Lee ES, Choi BI

***Ultras Med Biol* 2019;45(S1):S80**

<https://doi.org/10.1016/j.ultrasmedbio.2019.07.272>



Clinical Applications of Superb Microvascular Imaging in the Liver, Breast, Thyroid, Skeletal Muscle, and Carotid Plaques

Jiang ZZ, Huang YH, Shen HL, Liu XT
***J Ultrasound Med* 2019;38:2811-2820**

<https://doi.org/10.1002/jum.15008>



The Value of Superb Microvascular Imaging in Detecting Hepatic Artery Occlusion in Liver Transplantation: A Preliminary Study

Güven F, Karaca L, Ogul H, Sade R, Öztürk G, Kantarci M
***Ultras Quarterly* 2019;35(4):325-329**

<https://doi.org/10.1097/ruq.0000000000000416>



Superb Microvascular Imaging Improves Detection of Vascularity in Indeterminate Renal Masses

Leong JY, Wessner CE, Kramer MR, Forsberg F, Halpern EJ, Lyshchik A, Torkzaban M, Morris A, Byrne K, VanMeter M, Trabulsi EJ, Lallas CD, Eisenbrey

***J Ultrasound Med* 2020;39(10):1947-1955**

<https://doi.org/10.1002/jum.15299>



Improved detection of indeterminate renal mass vascularity with superb microvascular imaging

Leong JY, Wessner C, Kramer M, Forsberg F, Lyshchik A, Trabulsi E, Lallas C, Eisenbrey J

***J Urol* 2019;201suppl4:e997-e998**

<https://doi.org/10.1097/01.JU.0000557505.38582.6e>



Comparison of superb microvascular imaging to conventional color Doppler ultrasonography in depicting renal cortical microvasculature

Jing G, Thai A, Erpelding T

***Clinical Imaging* 2019;58:90-95**

<https://doi.org/10.1016/j.clinimag.2019.06.011>



Consistency of superb microvascular imaging and contrast-enhanced ultrasonography in detection of intraplaque neovascularization: A meta-analysis

Yang F, Wang C

***PLoS ONE* 2020;15(7):e0230937**

<https://doi.org/10.1371/journal.pone.0230937>



Impact of a novel ultrasound microvascular imaging and elastography on prostate cancer classification

Shen TT, Xue JL

***Transl Androl Urol*; 8(6): 696-702 (2019)**

<https://doi.org/10.21037/tau.2019.11.15>



Advanced ultrasound in the diagnosis of prostate cancer

Correas JM, Halpern EJ, Barr RG, Ghai S, Walz J, Bodard S, Dariane C, de la Rosette J

***World J Urol* 2021;39(3):661-676**

<https://doi.org/10.1007/s00345-020-03193-0>



Diagnostic Value of High Frame Rate Contrast-enhanced Ultrasonography and Post-processing Contrast Vector Imaging for Evaluation of Focal Liver Lesions: A Feasibility Study

Yoo J, Lee JM

***Ultras Med Biol* 2020;46(9):2254-2264**

<https://doi.org/10.1016/j.ultrasmedbio.2020.05.001>



Vascular pattern and diagnostic accuracy of contrast-enhanced ultrasound (CEUS) in spleen alterations

Lerchbaumer MH, Kleemann T, Jung EM, Nagel S, Hamm B, Fischer T

***Clin Hemorheol Microcirc* 2020;75(2):177-188**

<https://doi.org/10.3233/ch-190758>



Value of contrast-enhanced ultrasound (CEUS) in Focal Liver Lesions (FLL) with inconclusive findings on cross-sectional imaging

Auer TA, Fischer T, Garcia SRM, Penzkofer T, Jung EM, Hamm B, Lerchbaumer MH

***Clin Hemorheol Microcirc* 2020;74(3):327-339**

<https://doi.org/10.3233/CH-190718>



Hookwire-guided Sentinel Lymph Node Biopsy Using Contrast-enhanced Ultrasonography Followed by a One-step Nucleic Acid Amplification (OSNA) Assay for Breast Cancer

Miyake T, Shimazu K, Tanei T, Naoi Y, Kagara N, Shimoda M, Kim SJ, Noguchi S

***Anticancer Research* 2019;39(11):6183-6192**

<https://doi.org/10.21873/anticancerres.13826>



Diagnostic performance of contrast-enhanced ultrasound (CEUS) in testicular pathologies: Single-center results

Lerchbaumer MH, Auer TA, Marticorena GS, Stephan C, Hamm B, Jung, EM, Fischer T

***Clin Hemorheol Microcirc* 2019;73(2):347-357**

<https://doi.org/10.3233/CH-190579>

Smart Fusion / Smart Navigation



Application of ultrasound fusion imaging technique for unilateral percutaneous vertebroplasty in treatment of osteoporotic thoracolumbar compression fracture

Li S, Mi S, Guo R, Ma X, Han M

***J X-Ray Science and Technology* 2020;28(1):171-183**

<https://doi.org/10.3233/XST-190563>

Smart Fusion / Smart Navigation



Evaluation of the use of intraoperative real-time virtual sonography with Sonazoid enhancement for detecting small liver metastatic lesions after chemotherapy in hepatic resection

Araki K, Harimoto N, Muranushi R, Hoshino K, Hagiwara K, Yamanaka T, Ishii N, Tsukagoshi M, Igarashi T, Watanabe A, Kubo N, Shirabe K

***J Medical Investigation* 2019;66(3.4):319-323**

<https://doi.org/10.2152/jmi.66.319>

Smart Fusion / Smart Navigation



Impact of an ultrasound-guided radiofrequency ablation training program on the outcomes in patients with hepatocellular carcinoma

Takamatsu RT, Okano A, Yamakawa G, Mizukoshi K, Obayashi H, Ohana M

***Diagn Intervent Imaging* 2019;100(12):771-780**

<https://doi.org/10.1016/j.diii.2019.08.004>



Additive Value of Transrectal Systematic Ventral Biopsies in Combination with Magnet Resonance Imaging/Ultrasound Fusion-Guided Biopsy in Patients with 3 or More Negative Prostate Biopsies

Maxeiner A, Nest AM, Stephan C, Cash H, Baur ADJ, Fischer T, Kilic E, Piper SK, Nowak CP, Busch J, Miller K, Mangz J

***Urol Int* 2020;104(3-4):205-213**

<https://doi.org/10.1159/000504266>



Percutaneous Trans-venous Femoropopliteal Bypass in Long Occlusions of the Superficial Femoral Artery

Touma J, Senemaud J, Jaziri A, Cochenec F, & Desgranges P

***Cardiovasc Intervent Radiol* 2019;42(12):1800–1805**

<https://doi.org/10.1007/s00270-019-02310-w>



Exclusive use of ultrasound for locating optimal LVA sites – A descriptive data analysis

Czedik-Eysenberg M, Steinbacher J, Obermayer B, Yoshimatsu H, Hara H, Mihara M, Tzou CHJ, Meng S

***J Surg Oncol* 2020;121(1):51– 56**

<https://doi.org/10.1002/jso.25728>



Validation of US evaluation of ulcerative colitis activity

Omotehara S, Nishida M, Kinoshita K, Onishi R, Onodera A, Sua M, Hasegawa T, Mitsumori D, Katsurada T, Teshima T

***Ultras Med Biol* 2019;45(7):1537-1544**

<https://doi.org/10.1016/j.ultrasmedbio.2019.02.018>



Mucinous cystic neoplasm of the pancreas assessed with a real-time three-dimensional imaging using a transesophageal echocardiography probe

Ishikawa T, Hirooka Y, Kawashima H, Ohno E, & Fujishiro M

***Clin J Gastroenterol* 2019;12:479–483**

<https://doi.org/10.1007/s12328-019-00975-x>



Pediatric imaging



Pancreas ultrasound two-dimensional shear wave elastography in healthy children

Qiu L, Trout AT, Bennett PS, Dillman JR

***Pediatr Radiol* 2021;51:403–409**

<https://doi.org/10.1007/s00247-020-04863-2>



Two-dimensional ultrasound shear wave elastography for identifying and staging liver fibrosis in pediatric patients with known or suspected liver disease: a clinical effectiveness study

Alhashmi GH, Gupta A, Trout AT, Dillman JR

***Pediatr Radiol* 2020;50:1255–1262**

<https://doi.org/10.1007/s00247-020-04720-2>



Frequency of technical success of two-dimensional ultrasound shear wave elastography in a large pediatric and young adult cohort: a clinical effectiveness study

Northern NA, Dillman JR, Trout AT

***Pediatr Radiol* 2019;49:1025–1031**

<https://doi.org/10.1007/s00247-019-04396-3>



Spleen stiffness by 2D shear wave elastography is the most accurate predictor of high-risk esophagogastric varices in children with biliary atresia

Yokoyama S, Ishigami M, Honda T, Kuzuya T, Ishizu Y, Ito T, Hirooka Y, Tanaka Y, Tainaka T, Shirota C, Chiba K, Uchida H, Fujishiro M

***Hepatol Res* 2019;49(10):1162–1168**

<https://doi.org/10.1111/hepr.13381>



Superb Microvascular Imaging in the Evaluation of Pediatric Graves Disease and Hashimoto Thyroiditis

Bayramoglu Z, Kandemirli SG, Sar Akyol ZN, Kardelen AD, Poyrazoglu S, Bas F, Darendeliler F, Adaletli I

***J Ultrasound Med* 2019;39(5):901-909**

<https://doi.org/10.1002/jum.15171>



Seeing the Unseen: Evaluating Testicular Vascularity in Neonates by Using the Superb Microvascular Imaging Ultrasound Technique

Ayaz E, Ayaz M, Öna CI, Yikılmaz A

***J Ultrasound Med* 2019;38(7):1847-1854**

<https://doi.org/10.1002/jum.14882>

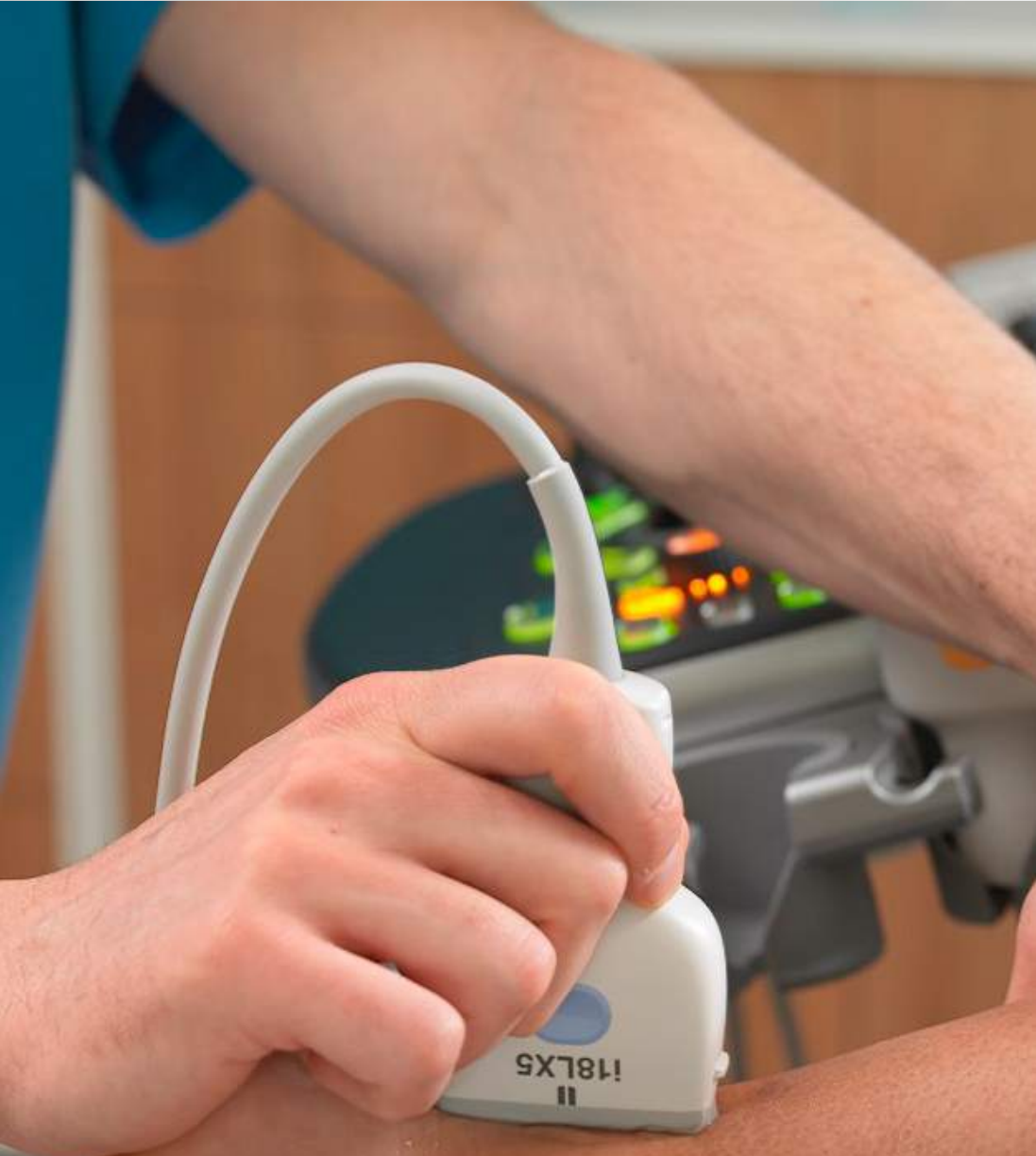

Microvessel ultrasound of neonatal brain parenchyma: feasibility, reproducibility, and normal imaging features by superb microvascular imaging (SMI)

Goeral K, Hojreh A, Kasprian G, Klebermass Schrehof K, Weber M, Mitter C, Berger A, Prayer D, Brugger PC, Vergesslich-Rothschild K, Patsch JM

***Eur Radiol* 2019;29:2127-2136**

<https://doi.org/10.1007/s00330-018-5743-1>



Musculoskeletal imaging



Correlation of glenohumeral internal rotation deficit with shear wave ultrasound elastography findings for the posterior inferior shoulder capsule in college baseball players

Park HJ, Jeon JH, Suh DK, Lee CS, Lee JH, Jeong WK

***J Shoulder Elbow Surg* 2021;30:1588–1595**

<https://doi.org/10.1016/j.jse.2020.09.036>



Shear-wave elastography of the ulnar collateral ligament of the elbow in healthy volunteers: a pilot study

Gupta N., Labis JS, Harris J, Trakhtenbroit MA, Peterson LE, Jack RA, McCulloch PC

***Skeletal Radiol* 2019;48(8):1241–1249**

<https://doi.org/10.1007/s00256-019-3162-2>



Change in Shear Elastic Modulus of Thigh Muscle by Changing Muscle Length Using Ultrasound Shear Wave Elastography in Beagle Dogs

Shimizu M, Ito Y

***Vet Comp Orthop Traumatol* 2019;32(06):454-459**

<https://doi.org/10.1055/s-0039-1692449>



Influence of pennation angle on measurement of shear wave elastography: in vivo observation of shear wave propagation in human pennate muscle

Chino K, Takahashi H

***Physiol Meas* 2018;39(11):115003**

<https://doi.org/10.1088/1361-6579/aae7e2>



Carpal tunnel ultrasound: is the “safe zone” on the ulnar side of the median nerve really avascular?

Sergeant AC, Badr S, Saab M, Demondion X, Cotten A, Jacques T
Eur Radiol 2020;**30(2):887-894**

<https://doi.org/10.1007/s00330-019-06416-0>



Comparison of three ultrasonographic examinations on the synovial membrane vascularity of RA patients

Jin X, Li F, Liu H, Wang H, Du J
Phys Eng Sci Med 2020;**43(2):617-622**

<https://doi.org/10.1007/s13246-020-00862-7>



Superb microvascular imaging (SMI) in the evaluation of musculoskeletal disorders: a systematic review

Gitto S, Messina C, Chianca V, Tuscano B, Lazzara A, Corazza A, Pedone L, Albano D, Sconfienza LM
Radiol Med 2020;**125(5):481-490**

<https://doi.org/10.1007/s11547-020-01141-x>



The superb microvascular imaging is more sensitive than conventional power Doppler imaging in detection of active synovitis in patients with rheumatoid arthritis

Lee GY, Kim S, Choi ST, Song JS
Clin Rheumatol 2019;**38(9):2613-2620**

<https://doi.org/10.1007/s10067-019-04550-0>



Ultrasound Microflow Imaging Technology for Diagnosis of Adhesive Capsulitis of the Shoulder

Kim DH, Choi YH, Oh S, Kim HJ Chai JW

***J Ultrasound Med* 2019;39:967-976**

<https://doi.org/10.1002/jum.15181>



Characterization of Carpal Tunnel Syndrome using High Frequency Ultrasound Imaging: A Comparison of Ultrasonic Features in the Median Nerve

Nam K, Peterson SM, Wessner CE, Machado P, Forsberg F

2019 IEEE International Ultrasonics Symposium 2019:1433-1436

<https://doi.org/10.1109/ULTSYM.2019.8926247>



Detection of Increased Vascular Signal in Arthritis-Prone Rats Without Joint Swelling Using Superb Microvascular Imaging Ultrasonography

Horie T, Nishida M, Tanimura S, Kamishima T, Tamai E, Morimura Y, Nishibata Y, Masuda S, Nakazawa D, Tomaru U, Atsumi T, Ishizu A

***Ultras Biol Med* 2019;45(8):2086-93**

<https://doi.org/10.1016/j.ultrasmedbio.2019.04.002>



Reliability and Validity of Ultrasonography for Measurement of Hamstring Muscle and Tendon Cross-Sectional Area

Kositsky A, Gonçalves BA, Stenroth L, Barrett RS, Diamond LE, Saxby DJ

***Ultras Biol Med* 2020;46(1):55-63**

<https://doi.org/10.1016/j.ultrasmedbio.2019.09.013>



Clinical utility and potential of ultrasound in osteoarthritis

Okano T, Mamoto K, Di Carlo M, Salaffi F

***Radiol Med* 2019;124:1101–1111**

<https://doi.org/10.1007/s11547-019-01013-z>



Women's Health imaging



Combination of Quantitative Parameters of Shear Wave Elastography and Superb Microvascular Imaging to Evaluate Breast Masses

Lee EJ, Chang YW

***Korean J Radiol.* 2020 Sep;21(9):1045-1054 (open access)**

<https://doi.org/10.3348/kjr.2019.0765>



Combined use of strain elastography and superb microvascular imaging with grayscale ultrasound according to the BI-RADS classification for differentiating benign from malignant solid breast masses

Liang M, Ou B, Wu J, Xiao X, Ruan J, Tian J, Xu X, Wang B, Yang H, Luo B

***Clin Hemorheol Microcirc* 2020;74(4):391-403**

<https://doi.org/10.3233/ch-190693>



What shear wave elastography parameter best differentiates breast cancer and predicts its histologic aggressiveness?

Kim H, Lee J, Kang BJ, Kim SH

***Ultrasonography* 2021;40(2):265-273**

<https://doi.org/10.14366/usg.20007>



Use of shear wave elastography on the maternal cervix to recognize cervical insufficiency using a transabdominal ultrasound approach

O'Hara S, Zelesco M, Sun Z

***Australasian J Ultras Med* 2021;24(2):89-98**

<https://doi.org/10.1002/ajum.12236>



Tumor stiffness measured by shear wave elastography correlates with tumor hypoxia as well as histologic biomarkers in breast cancer

Yoo J, Seo BK, Park EK, Kwon M, Jeong H, Cho KR, Woo OH, Song SE, Cha J

***Cancer Imaging* 2020;20,85**

<https://doi.org/10.1186/s40644-020-00362-7>




US-Elastography for Breast Lesion Characterization: Prospective Comparison of US BIRADS, Strain Elastography and Shear wave Elastography

Cantisani V, David E, Barr RG, Radzina M, de Soccio V, Elia D, De Felice C, Pediconi F, Gigli S, Occhiato R, Messineo D, Fresilli D, Ballesio L, D'Ambrosio F

***Ultraschall Med* 2021;42(05):533-540**

<https://doi.org/10.1055/a-1134-4937>



Shear Wave Elastography of the Maternal Cervix: A Comparison of Transvaginal and Transabdominal Ultrasound Approaches

O'Hara S, Zelesco M, Sun Z

***JUM (AIUM)* 24 August 2020(abstract)**

<https://doi.org/10.1002/jum.15440>



Added Value of the Vascular Index on Superb Micro-vascular Imaging for the Evaluation of Breast Masses: Comparison With Grayscale Ultrasound

Chae EY, Yoon GY, Cha JH, Shin HJ, Choi WJ, Kim HH

***J Ultras Med* 2021;40(4):715-723**

<https://doi.org/10.1002/jum.15441>



Reproducibility and diagnostic performance of the vascular index of superb microvascular imaging in real-time breast ultrasonography for evaluating breast masses

Lee EJ, Chang YW, Oh E, Hwang J, Kim HJ, Hong SS

***Ultrasonography* 2021; 40(3): 398406**

<https://doi.org/10.14366/usg.20153>



Breast Ultrasound Microvascular Imaging and Radiogenomics

Park AY, Seo BK, Han MR

***Korean J Radiol* 2021;22(5):677-687**

<https://doi.org/10.3348/kjr.2020.1166>



The Vascular Index of Superb Microvascular Imaging Can Improve the Diagnostic Accuracy for Breast Imaging Reporting and Data System Category 4 Breast Lesions

Cai SM, Wang HY, Zhang XY, Zhang L, Zhu QL, Li JC, Sun Q, Jiang YX

***Cancer Manag Res* 2020;12:1819-1826**

<https://doi.org/10.2147/CMAR.S242101>



A comparative study on superb microvascular imaging and conventional ultrasonography in differentiating BI-RADS 4 breast lesions

Zhu YC, Zu DM, Zhang Y, Shan J, Shi XR, Deng SH and Jiang Q

***Oncol Lett* 2019;18:3202-3210**

<https://doi.org/10.3892/ol.2019.10603>



Evaluation of plasma cell mastitis with superb microvascular imaging

Zhu YC, Zhang Y, Deng SH, Jiang Q, Sh XR, Feng LL

***Clin Hemorheol Microcirc* 2019;72(2):129-138**

<https://doi.org/10.3233/ch-180468>

SMI, CEUS



A Prospective Study on the Value of Ultrasound Microflow Assessment to Distinguish Malignant from Benign Solid Breast Masses: Association between Ultrasound Parameters and Histologic Microvessel Densities

Park AY, Kwon M, Woo OH, Cho KR, Park EK, Cha SH, Song SE, Lee JH, Cha J, Son GS, Seo BK

***Korean J Radiol* 2019;20(5):759-772**

<https://doi.org/10.3348/kjr.2018.0515>

SMI, CEUS



Radiogenomic Analysis of Breast Cancer by Using B-Mode and Vascular US and RNA Sequencing

Park AY, Han MR, Park KH, Kim JS, Son GS, Lee HY, Chang YW, Park EK, Cha SH, Cho Y, Hong H, Cho KR, Song SE, Woo OH, Lee JH, Cha J, Seo BK

***Radiology* 2020;295(1):24-34**

<https://doi.org/10.1148/radiol.2020191368>

Smart Fusion / Smart Navigation



Ultrasound-guided targeted biopsies of CT-based radiomic tumour habitats: technical development and initial experience in metastatic ovarian cancer

Beer L, Gonzalez PM, Ortet MD, Reinius M, Rundo L, Woitek R, Ursprung S, Escudero L, Sahin H, Funingana IG, Ang JE, Linan MJ, Lawton T, Phadke G, Davey S, Nguyen NQ, Markowet F, Brenton JD, Crispin-Ortuzar M, Addley H, Sala E

***Eur Radiol* 2021;31:3765-3772**

<https://doi.org/10.1007/s00330-020-07560-8>



A Rare Case of a Woman Presenting with Axillary Silicone lymphadenopathy accompanied by Extracapsular Siliconoma and Thickened Capsule after an Implant-based Augmentation Mammoplasty

Kim JH

***J Surg Open Access* 2021;7(2):**

<https://doi.org/10.16966/2470-0991.236>



Usefulness of second-look ultrasonography using anatomical breast structures as indicators for magnetic resonance imaging-detected breast abnormalities

Izumori A, Kokubu Y, Sato K, Gomi N, Morizono H, Sakai T, Horii R, Akiyama F, Iwase T, Ohno S

***Breast Cancer* 2020;27:129–139**

<https://doi.org/10.1007/s12282-019-01003-z>



Description of Two Cases of Anaplastic Large Cell Lymphoma Associated with a Breast Implant

Crèvecoeur J, Jossa V, Somja J, Parmentier JC, Nizet JL, Crèvecoeur A

***Case Reports in Radiology* 2019;ID6137198**

<https://doi.org/10.1155/2019/6137198>



Obstetric ultrasound



Superb microvascular imaging with Doppler luminance using an 18-MHz probe to visualize fetal intra-abdominal blood vessels and organ microvasculature

Hata T, Koyanagi A, Yamanishi T, Bouno S, Takayoshi R, Miyake T

***J Perinat Med* 2020;48(2):184–188**

<https://doi.org/10.1515/jpm-2019-0411>



Sono-embryological assessments of a true knot that developed into a hypercoiled cord and circumvallate placenta

Hasegawa J, Furuya N, Doi M, Sasaki T, Takagi M, Suzuki N

***J Matern Fetal Neonatal Med* 2019; online ahead of print**

<https://doi.org/10.1080/14767058.2019.1704247>



Superb Microvascular Imaging of Retained Placenta with Placenta Accreta Spectrum

Hata T, Hanaoka U, Mori A, Yamamoto K, Tenkumo C, Mori N, Kanenishi K, Tanaka H

***Donald School J Ultras Obstet Gynecol* 2019;13(3):85–87**

<https://doi.org/10.5005/jp-journals-10009-1600>



Characterization of Placental Microvasculature Using Superb Microvascular Imaging

Mack LM, Mastrobattista JM, Gandhi R, Castro EC, Burgess APH, Lee W

***J Ultras Med* 2019;38(9):2485–2491**

<https://doi.org/10.1002/jum.14919>



Sonohistological findings of the placenta accreta spectrum

Furuya, N, Hasegawa, J, Homma C, Suzuki N
Ultras Obstet Gynecol 2019;54(S1):379-379

<https://doi.org/10.1002/uog.21587>



Cardiac time intervals and myocardial performance index for prediction of twin-twin transfusion syndrome

Gijtenbeek M, Eschbach SJ, Middeldorp JM, Klumper FJCM, Slaghekke F, Oepke D, Haak MC

***Prenatal Diagnosis* 2021; online ahead of print**

<https://doi.org/10.1002/pd.5981>



The assessment of the fetal heart function using two-dimensional speckle tracking with a high frame rate

Ohira A, Hayata K, Mishima S, Tani K, Jota M, Mitsui T, Eto E, Masuyama H

***Early Hum Dev* 2020;151:105160**

<https://doi.org/10.1016/j.earlhumdev.2020.105160>



Normal Fetal Ventricular Strain by 2-Dimensional Speckle Tracking Echocardiography With Novel Imaging Modality With Higher Frame Rate and Spatial Resolution

Takei K, Yasukochi S, Takigiku K, Tanaka N, Yonehara K, Obinata H, Numata R, Koyama S, Masamoto M, Yamada Y

***Journal infoNov 2019 Circulation.* 2019;140: A14440 (abstract)**

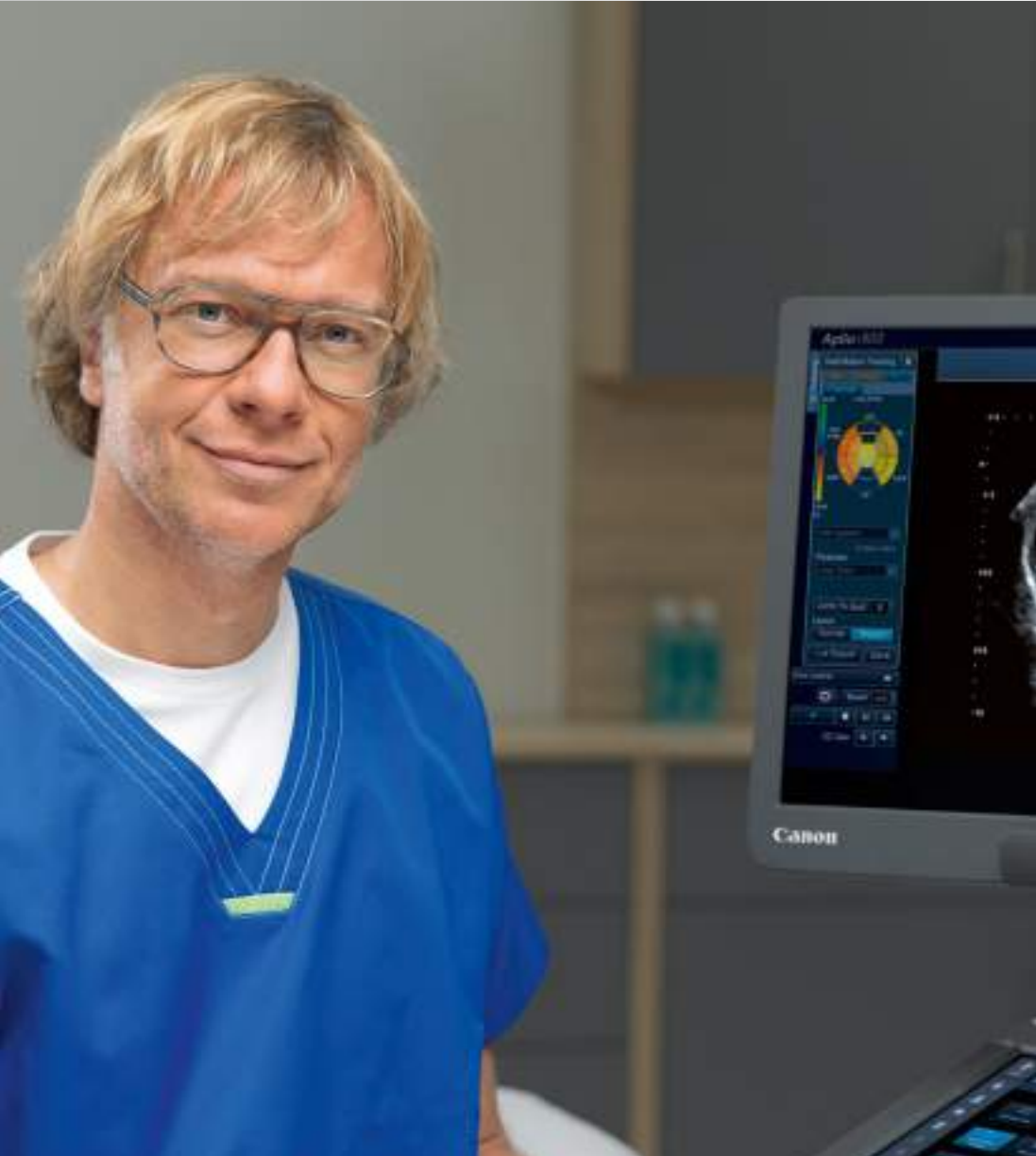https://www.ahajournals.org/doi/10.1161/circ.140.suppl_1.14440



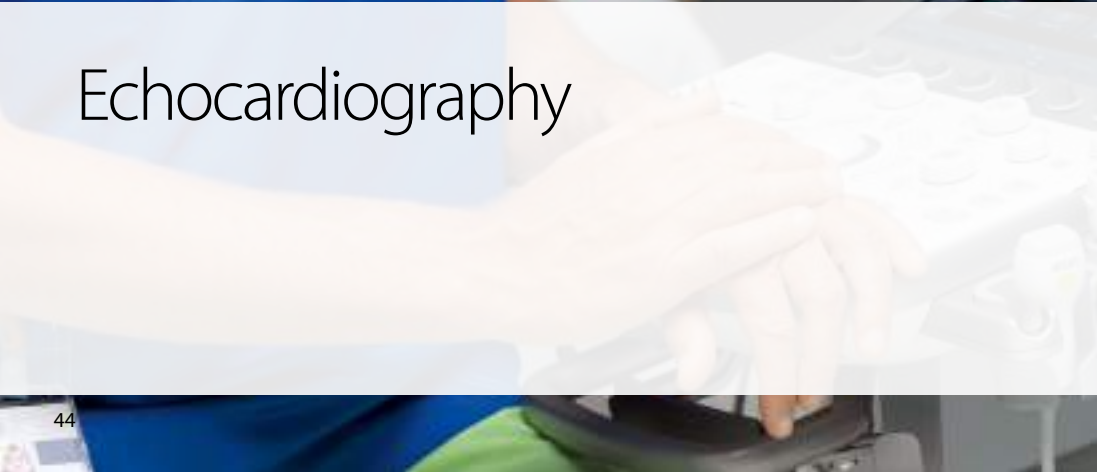
Placental function and fetal weight are associated with maternal hemodynamic indices in uncomplicated pregnancies at 35-37 weeks gestation

Coral Garcia-Gonzalez C, Samira Abdel-Azim S, Slavyana Galeva S, Georgios Georgiopoulos G, Kypros H. Nicolaides KH, Charakida M
AJOG 2020;222(6):604.E1-604.E10

<https://doi.org/10.1016/j.ajog.2020.01.011>



Echocardiography





Intervendor comparison of mitral valve analysis software

Bratanoff M, Garwood S, Zhu Q, Vaitkeviciute I, Lin B, Mancina J, Fukuda S, Imamura T, Gorrissen W, Sugeng L

***Eur Heart J - Cardiovasc Imaging*;20(S1):i1214**

<https://doi.org/10.1093/ehjci/jev274>



Accuracy and reliability of novel semi-automated two-dimensional layer specific speckle tracking software for quantifying left ventricular volumes and function

Tetsuji Kitano, Yosuke Nabeshima, Yasuhiko Abe, Yutaka Otsuji, Masaaki Takeuchi

***PLoS ONE* 2019;14(8):e0221204**

<https://doi.org/10.1371/journal.pone.0221204>



Interplay between right atrial function and liver stiffness in adults with repaired right ventricular outflow obstructive lesions

Li VWY, So EKF, Li W, Chow PC, Cheung YF

***Eur Heart J - Cardiovasc Imaging* 2020;jeaa344**

<https://doi.org/10.1093/ehjci/jeaa344>



Ultrasound Imaging of the Abdominal Aorta: A Comprehensive Review

Fadel BM, Mohty D, Kazzi BE, Alamro B, Arshi F, Mustafa M, Echahidi N, Aboyans V

***JASE* 2021; online ahead of print**

<https://doi.org/10.1016/j.echo.2021.06.012>



Usefulness of cardiac fusion imaging with computed tomography and Doppler echocardiography in the assessment of conduit stenosis in complex adult congenital heart disease

Watanabe N, Toh N, Takaya Y, Nakayama R, Yokohama F, Osawa K, Miyoshi T, Akagi T, Kanazawa S, Ito H

J Cardiol 2021; online ahead of print

<https://doi.org/10.1016/j.jjcc.2021.06.008>



Evolution of echocardiography in adult congenital heart disease: from pulsed-wave Doppler to fusion imaging

Toh N, Akagi T, Kasahara S, Ito H

J Echocardiogr (2021); online ahead of print

<https://doi.org/10.1007/s12574-021-00533-w>

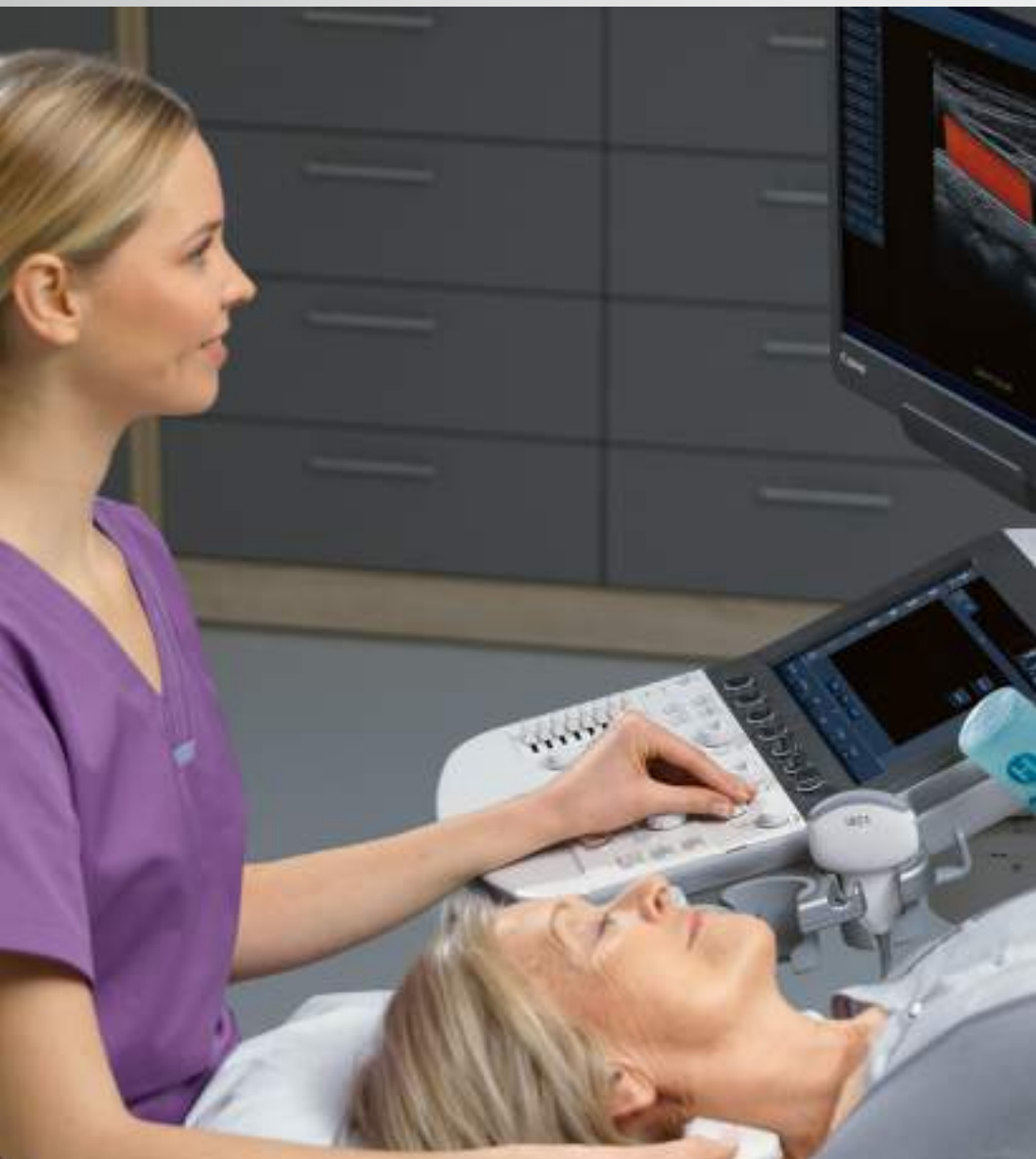

Access-site complications of transradial percutaneous coronary intervention using sheathless guiding catheters for acute coronary syndrome: a prospective cohort study with radial ultrasound follow-up

Isawa T, Horie K, Taguri M, Ootomo T

Cardiovasc Interv and Ther 2020;35:343–352

<https://doi.org/10.1007/s12928-019-00632-7>



Vascular imaging



Ultrasound assessment of tensile stress in carotid arteries of healthy human subjects with varying age

Luo X, Du L, Li Z

***BMC Med Imaging* 2019;19:93**

<https://doi.org/10.1186/s12880-019-0394-5>



Detection of Carotid Atherosclerotic Intraplaque Neovascularization Using Superb Microvascular Imaging: A Meta-Analysis

Song Y, Xing H, Zhang Z, Felix LO

***J Ultras Med* 2021; online ahead of print**

<https://doi.org/10.1002/jum.15652>



Carotid Plaque Neovascularization Detected With Superb Microvascular Imaging Ultrasound Without Using Contrast Media

Zamani M, Skagen K, Scott H, Lindberg B, Russell D, Skjelland M

***Stroke* 2019;50(11):3121–3127**

<https://doi.org/10.1161/STROKEAHA.119.025496>



Value of superb micro-vascular imaging in predicting ischemic stroke in patients with carotid atherosclerotic plaques

Yang DB, Zhou J, Feng L, Xu R, Wang YC

***World J Clin Cases* 2019;7(7):839–848**

<https://doi.org/10.12998/wjcc.v7.i7.839>

Canon

CANON MEDICAL SYSTEMS CORPORATION

<https://global.medical.canon>

©Canon Medical Systems Corporation 2021. All rights reserved.
Design and specifications are subject to change without notice.
MOIUS0129EA 2021-11 CMSC/Produced in Japan

Aplio and Made for Life are trademarks of Canon Medical Systems Corporation.

Hyperlinks and QR codes in this document are provided for convenience only.
Canon Medical Systems assumes no responsibility for the functionality of
external links or for their content.

Made For life